

**COMPLETE REPAIR OF TETRALOGY OF FALLOT (TOF) ON BEATING  
HEART SURGERY WITHOUT AORTIC CROSS CLAMPING : REPORT OF  
A CASE**

Gerardo AK Laksono <sup>1)</sup>, Heroe Soebroto <sup>2)</sup>, Paul L Tahalele <sup>1)\*)</sup>

**ABSTRACT**

**Introduction:** Reperfusion injury is a well-known phenomenon that occurred in cardioplegic techniques with cardiopulmonary bypass. Therefore great effort is made to prevent reperfusion injury. Beating Heart Continuous Coronary Perfusion (BHCCP) surgery is one of the alternative techniques to improve an ischemic reperfusion injury in open-heart surgery, either in pediatric or in adult. This technique can be done in complete repair of tetralogy of Fallot (TOF). **Purpose:** To report our first experience in doing complete repair of TOF using beating heart technique without aortic cross-clamping **Case Report:** A five-year-old boy came on to ER on January 6th, 2012, with a history of cyanotic since birth. His echocardiography and catheterization concluded a tetralogy of Fallot with a McGoon ratio of 1.95 (the diameter of RPA and LPA were 9.14 mm and 8.79 mm, respectively). A complete repair of TOF was done using beating heart surgery without aortic cross-clamping technique. One month post-surgery evaluation, there weren't any neurological or motor disorders. Echocardiography results showed no residual pulmonary stenosis, but 0.2 mm residual VSD was found. **Conclusion:** This heart rate technique is an alternative method of myocardial protection in cardiac surgery. In several cardiac centres globally, this technique is relatively safe and can be used during surgery, especially in the total correction of TOF.

**Keywords:** Tetralogy of Fallot, TOF, Beating Heart Continuous Coronary Perfusion, Beating Heart Surgery

**ABSTRAK**

**Pendahuluan :** Cedera reperfusi adalah fenomena yang sering terjadi, yang dapat terjadi pada teknik pembedahan menggunakan kardioplegia dengan mesin *bypass* kardiopulmonar, sehingga diperlukan upaya pencegahan. Pembedahan dengan tehnik jantung berdenyut BHCCP adalah salah satu teknik alternatif untuk

meningkatkan cedera reperfusi iskemik pada pembedahan open heart baik pada anak-anak atau dewasa. Teknik ini dapat dilakukan pada perbaikan lengkap tetralogy of fallot. **Tujuan** : Melaporkan pengalaman pertama kami dalam melakukan koreksi total TOF menggunakan teknik BHCCP. **Laporan kasus** : Anak laki-laki berusia 5.5 tahun datang pada tanggal 6 Januari 2012 dengan riwayat cyanosis sejak lahir. EKG dan kateterisasi menyimpulkan adanya TOF dengan rasio McGoo. 1.95 (diameter RPA dan LPA masing-masing 9.14 mm dan 8.79 mm). Koreksi total TOF dilakukan dengan pembedahan BHCCP. Evaluasi pasca 1 bulan operasi, tidak ditemui adanya kelainan neurologis maupun motorik. Hasil EKG menunjukkan tidak ada stenosis residual katup pulmonal, namun ditemukan 0.2mm VSD residual. **Kesimpulan**: Teknik jantung berdenyut ini merupakan suatu alternatif metode proteksi miokard pada pembedahan jantung. Pada beberapa pusat jantung di dunia, teknik ini relatif aman dan dapat digunakan pada saat pembedahan jantung khususnya pada total koreksi TOF.

**Kata Kunci:** *Tetralogy of Fallot, TOF, Beating Heart Continuous Coronary Perfusion, Bedah Jantung Berdenyut*

---

1) Surgery Department, Faculty of Medicine, Widya Mandala Surabaya Catholic University  
Email : Pltahalele@yahoo.com 2) Thoracic, Cardiac and Vascular Surgery Department, Faculty  
of Medicine Universitas Airlangga, Dr. Soetomo General Hospital Surabaya Indonesia \*)  
President of Indonesian Association of Thoracic, Cardiac and Vascular-Endovascular Surgeons  
\*) President of International College of Surgeons Indonesia Section

## INTRODUCTION

The two most common causes of morbidity and mortality in open-heart surgery are the side effects of prolonged CPB use and postoperative myocardial dysfunction due to reperfusion injury caused by myocardial ischemia during the cardiac arrest phase (1). Myocardial protection is critical in both pediatric and adult open-heart surgery. The primary distinction between cardiac

surgery in congenital heart disease and acquired heart disease is that most patients with congenital heart disease have normal myocardium and coronary artery flow (2). The main issue congenital heart surgeons face when it comes to protecting the myocardium during cardiac surgery is the change in the maturity of the myocardium (2). To avoid the possibility of reperfusion injury caused by cardioplegia, the Beating

Heart technique is the technique of choice.

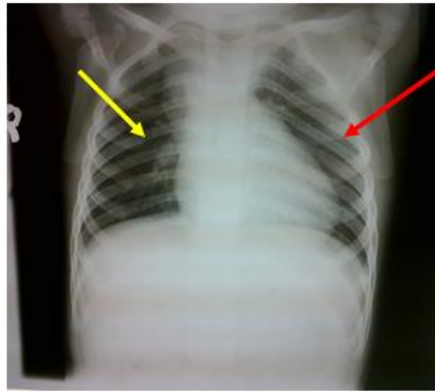
Tetralogy of Fallot (TOF) is a blue congenital heart defect that includes the following components: (a) ventricular septal defect, (b) pulmonary stenosis, (c) right ventricular hypertrophy, and (d) overriding aorta. TOF occurs at a rate of 400 per million live births (3). Surgery, both conventional and recently using beating heart techniques, can be used to treat this TOF. Ansheung M et al. (2008) reported 36 TOF cases wholly corrected with a pulsed heart technique (4). Surabaya Heart Center in Indonesia reported the first successful total corrective surgery for TOF using a pulsed heart technique without aortic cross-clamping in a 5-year-old boy.

### **CASE REPORT**

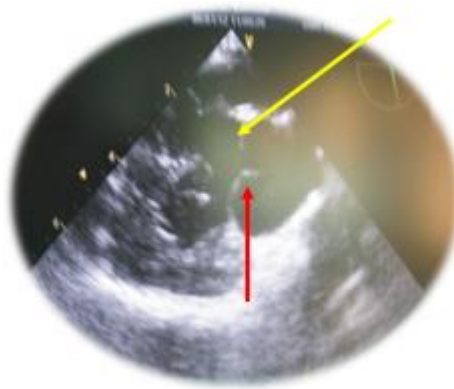
The patient is a 5-year-old boy who weighs 19 kg. The Public Health Center referred the patient after reports of the boy being blue since birth and always squatting when performing strenuous activities. There was cyanosis of the lips and

soft palate and clubbing fingers on the hands and feet on physical examination. A systolic thrill and a systolic murmur were detected along the left parasternal area during a cardiac examination.

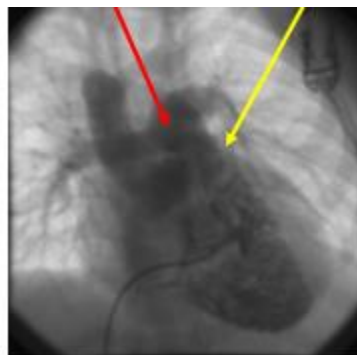
A laboratory examination revealed Hb: 18.1 with hematocrit: 54 and O<sub>2</sub> saturation (by pulse oximetry) of approximately 80%. The chest X-ray reveals a "boot-shaped" appearance and decreased pulmonary vascularity/oligemia (see Figure 1). Echocardiography reveals an image of the site of solitus; AV-VA concordance; right atrial and ventricular dilatation; severe pulmonary stenosis with (PG: 87.62mmHg) with left and right pulmonary artery diameters of 0.49 cm and 0.46cm, respectively; and a Ventricle Septal Defect (VSD) of about 1.8 cm. Figure 2 depicts chest X-ray result. The catheterization examination revealed a TOF with a McGoon ratio of 1.95 (right and left pulmonary artery diameters were 9.14 mm and 8.79 mm, respectively); no coronary anomalies were discovered (see Figure 3).



**Figure 1.** Chest X-ray shows a "Boot Shaped" image (red arrow) & decreased bronchovascular pattern (yellow arrow)



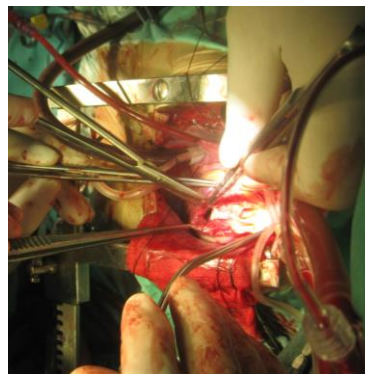
**Figure 2.** An overriding aorta (yellow arrow), perimembranous VSD (red arrow), and pulmonary stenosis (not shown in the image) are all visible on echocardiography.



**Figure 3.** Catheterization of the patient reveals a narrowing in the infundibulum area (yellow arrow) and the confluence of the right and left pulmonary arteries (red arrow)

It was decided that the patient would have total correction surgery. The median sternotomy is used to gain access. The pericardium has been prepared for implantation of the transannular patch. Aortic cannulation and bicaval were performed after heparinization (3mg/kg). In the right superior pulmonary vein, an LV vent cannula was inserted. The aorta is cannulated with a cardioplegic catheter. The cardiopulmonary bypass machine is then activated. The pulse rate is kept at around 80 beats per minute. The body's temperature drops by about 32-34°C. The mean arterial pressure (MAP) is kept between 50 and 60 mmHg, and the flow rate of the CPB machine is between 3.0 and 3.4 L/min/m<sup>2</sup>. The patient is in the Trendelenburg position. The pulmonary artery is then opened and

evaluated with a bouginage, inserted up to 12 mm into the right and left pulmonary arteries (half size: 9mm). There was also severe infundibulum stenosis and a bicuspid pulmonary valve. Following the opening of the right atrium, a secundum atrial septal defect (about 2 cm) was observed, and blood was evacuated from the right atrium and a portion of the left atrium via a cannula inserted through the right superior pulmonary vein (flow rate of about 100-200 ml/min). A VSD of about 30 mm and severe infundibular stenosis were discovered during a later evaluation through the right atrium. Following transpulmonary resection of the infundibulum (see figure 5), the Right Ventricular Outflow Tract (RVOT) was evaluated using a bouginage, inserted to a size of 14 mm (full size:11-12 mm).

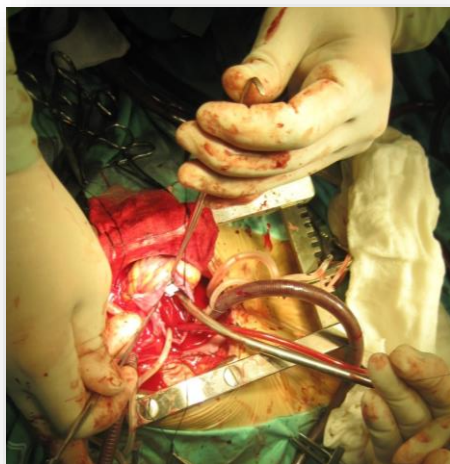


**Figure 5.** The Mean Artery Pulmonary (MAP) and RVOT were opened to reveal infundibulum stenosis, followed by pulmonary resection.

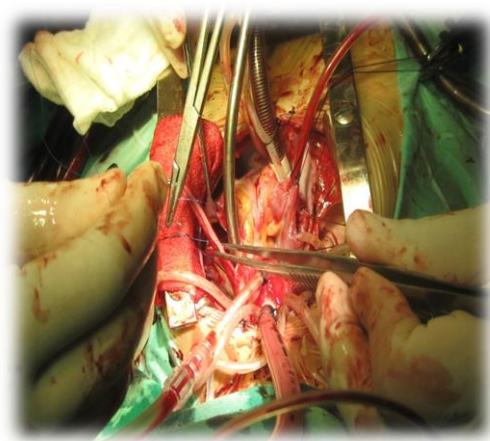
In a throbbing heart condition, the VSD was closed with a 0.4 mm Goretex patch applied continuously with prolene 5.0. (see Figure 6.a). Simultaneously, the body temperature gradually rises. The ASD secundum is then closed while the left heart is

de-airing through the LA vent. The pericardium was then used to place a transannular patch on the RVOT ( (see Figure 6.b). The right atrium is then closed while the right heart is de-airing.

6.a



6.b

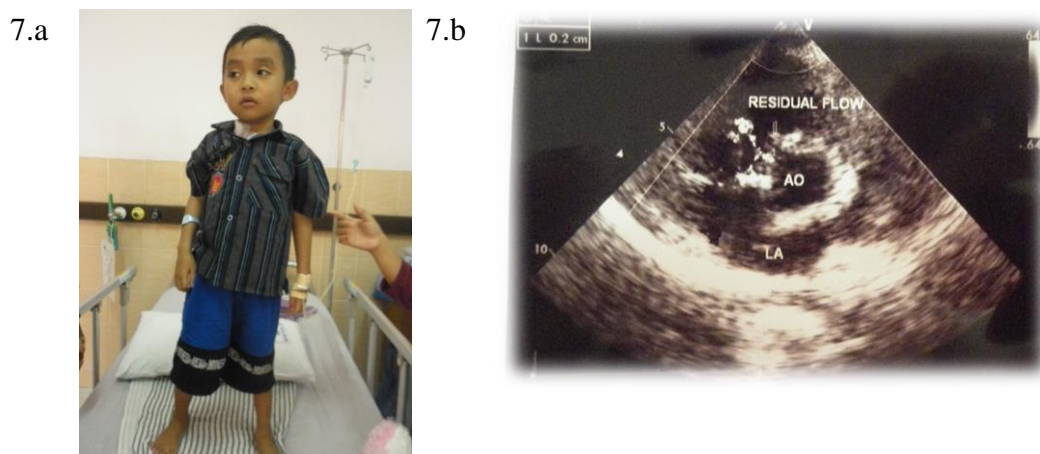


**Figure 6.** a) VSD closure with Goretex patch, b) RVOT closure with transannular patch

The CPB machine gradually weans until it stops. When hemodynamically stable, proceed with successive inferior and superior vena cava decannulation. After TEE revealed the absence of air in the left atrium and left ventricle, the LV vent cannula was removed. The patient was then given protamine (1:1 dose with heparin), followed by aortic decannulation. By leaving a drain, the operating field is closed. The time

spent in the heart-lung machine is approximately 116 minutes.

The patient was admitted to the intensive care unit with blood pressures ranging from 70-80/40-50 (60), a pulse rate of 150 beats per minute, a central venous pressure of 9-10 mmHg, and milrinone support of 0.25 mcg /kg/m. The average length of time on the ventilator is 8 hours, and the average length of ICU care is 40 hours



**Figure 7.** a) Clinical patient 3 days after surgery, b) Echocardiography showing postoperative residual VSD

Clinically, the patient had no neurological deficit after surgery (see Figure 7). One day after surgery, an echocardiogram revealed no residual pulmonary stenosis (PG:11.8 mmHg) or tricuspid regurgitation but with 0.2 mm residual VSD. The patient's clinical evaluation one month after surgery revealed no neurological or motor disorders. There was no residual pulmonary stenosis found on echocardiography, but there was a 0.2 mm residual VSD.

## DISCUSSION

Myocardial ischemia caused by aortic cross clamps, cardioplegia, and reperfusion injury is still a major concern in cardiac surgery. Myocardial oedema is frequently caused by reduced myocardial contraction and impaired lymphatic

flow, both caused by cardioplegia. After the aortic cross-clamp is removed, the problem of reperfusion injury remains unavoidable (3). Traditional myocardial protection strategies can also result in left ventricular dysfunction, which is especially important in preoperative myocardial dysfunction patients (4). Many experts use the beating heart technique to avoid ischemia problems caused by traditional myocardial protection methods. (1,4)

The heartbeat technique, where it beats when the heart is empty (empty beating), will reduce the heart's workload. In several clinical and experimental studies, this heart rate technique provides several advantages, including:

- No reperfusion injury.

- Reduced cardiac workload.
- Reduced cardiopulmonary bypass time.
- Evaluation of the mitral valve can be carried out as physiologically as possible, given that the heart is still beating.
- In the case of a VSD, facilitate the evaluation of the presence of a residual VSD or small VSD.
- Minimal use of inotropes.
- Easy to evaluate if there is a block in the conduction pathway.

The disadvantages are as follows:

- In some cases, this technique does not provide adequate exposure to the operating field;
- It increases red blood cell breakdown; and
- It is a more complicated surgical technique (5-14).

Some factors to consider when performing heart surgery with a beating heart technique are as follows (4): (a). During surgery, the temperature is adjusted as needed. The temperature of the priming

solution was kept above 32°C . Then it was reduced to 32-34°C. With this body temperature condition, it is hoped that the incidence of ventricular fibrillation will be reduced. Furthermore, this mild hypothermic condition is required to reduce the pulse rate (around 60 times per minute), cardiac muscle contractility, and metabolic rate. Gersak and Sutlik et al. used this technique under normothermic conditions with pulse rates ranging from 50 to 80 beats per minute (6.7). According to Kaukoranta et al., mild hypothermic conditions offer better myocardial protection than normothermic conditions. We chose to use a mild hypothermic condition in our case. (b) This will ensure a smooth operation by providing an optimal operating field of view. The condition of coronary blood flow is not blocked in the pulsed heart technique, and left to right gout will interfere with the operator's field of view. To keep the surgical field of view from becoming clogged with blood, a suction catheter is used to suck blood and air.

A Foley catheter can also be used to temporarily close the gout-



causing defect. A cardioplegic arrest is still required in some cases to provide an optimal operating field of view. (c) Last but not least, air embolism should be avoided during the procedure. Air embolism can occur when the pressure in the aorta is lower than the pressure in the left ventricle during antegrade perfusion. Maintaining left ventricular ventilation so that the pressure equals atmospheric pressure and aortic pressure in the 60 mm Hg range in adults and 50 mm Hg range in children is critical.

In retrograde perfusion, air embolism can be avoided by installing aortic cross clamps. Mo A et al. discovered that there was no incidence of stroke caused by air embolism in 701 heart surgery cases using a pulsed technique (4). Karadeniz et al. discovered no statistically significant difference in the occurrence of neurologic deficits between surgical heartbeats techniques and cardiac arrest (16). According to Salerno et al., air embolism can be avoided by inducing ventricular fibrillation and left ventricular decompression via the cardiac apex (17,18). In this case, we take several

precautions to avoid the occurrence of air embolism, including (a). The patient is in the Trendelenburg position (b). Installation of a left ventricular venting cannula in the right superior pulmonary vein to suction air and blood (c). Aortic valve competence evaluation; (d). The left ventricle pressure is attempted to be lower than the aortic pressure.

The first time congenital heart surgery with a pulsed technique was performed in TOF in Indonesia, precisely in Surabaya. In this case, the benefits of using this heart rate technique include: (a) less time on the ventilator and in the intensive care unit and (b) the use of low doses of inotropes.

## **CONCLUSION**

Cardiac surgery with the pulsed heart technique can be used to treat congenital or acquired heart defects, particularly in patients with cardiac hypertrophy and low ejection fractions (4). In cardiac surgery, this heart rate technique is an alternative method of myocardial protection. This technique is relatively safe and can be used during cardiac surgery in some cardiac centres worldwide.

## REFERENCES

1. Babaroglu S, Yay K, Parlar AI, Ates C, Mungan U, Cicekcioglu F, et al. Beating heart versus conventional mitral valve surgery. *Interactive cardiovascular and thoracic surgery*. 2011;12(3):441-7. Epub 2010/12/24.
2. Jonas AR HR, La Pierre R, Matte G, editor. Myocardial protection. first ed. Great Britain: Hodder Arnold, An Hachette UK company 2004.
3. Mehlhorn U, Allen SJ, Adams DL, Davis KL, Gogola GR, Warters RD. Cardiac surgical conditions induced by beta-blockade: effect on myocardial fluid balance. *Ann Thorac Surg* 1996;62:143–150.
4. Mo A, Lin H, Wen Z, Lu W, Long X, Zhou Y. Efficacy and Safety of On-Pump Beating Heart Surgery. *Ann Thorac Surg* 2008;86:1914-8.
5. Hui L, Wei H, Shifeng W, et al. Aortic valve replacement on the beating heart with continuous retrograde coronary sinus perfusion. *J Guangxi Med Univ* 1996;13:4–6.
6. Gersak B, Sutlic Z. Aortic and mitral valve surgery on the beating heart is lowering cardiopulmonary bypass and aortic cross clamp time. *Heart Surg Forum* 2002;5:182– 6.
7. Gersak B. Mitral valve repair or replacement on the beating heart. *Heart Surg Forum* 2000;3:232–7.
8. Yingbing X, Lin C, Xuefeng W, et al. On-pump beating-heart intracardiac procedures in 2100 cases. *Chin J ECC* 2006;4: 210–2.
9. Hui L, Wei H, Qingyun P, et al. Aortic valve and mitral valve replacement with retrograde coronary sinus perfusion on beating heart. *Chin J Thorac Cardiovasc Surg* 2001;17: 129–31.
10. Photiadis J, Asfour B, Sinzobahamvya N, et al. Improved hemodynamics and outcome after modified Norwood operation on the beating heart. *Ann Thorac Surg* 2006;81:976–81.
11. Panos A, Myers PO, Kalangos A. Novel technique for aortic arch surgery under mild

- hypothermia. *Ann Thorac Surg* 2008;85:347–8.
12. Battellini R, Rastan AJ, Fabricius A, Moscoso-Luduena M, Lachmann N, Mohr FW. Beating heart aortic valve replacement after previous coronary artery bypass surgery with a patent internal mammary artery graft. *Ann Thorac Surg* 2007;83:1206–9.
  13. Cicekcioglu F, Tutun U, Babaroglu S, et al. Aortic valve replacement with on-pump beating heart technique. *J Card Surg* 2007;22:211–4.
  14. Wang J, Liu H, Xiang B, et al. Keeping the heart empty and beating improves preservation of hypertrophied hearts for valve surgery. *J Thorac Cardiovasc Surg* 2006;132:1314–20.
  15. Behr L, Chetboul V, Sampedrano CC, et al. Beating heart mitral valve replacement with a bovine pericardial bioprosthesis for treatment of mitral valve dysplasia in a bull terrier. *Vet Surg* 2007;36:190–8.
  16. Kaukoranta P, Lepojärvi M, Nissinen J, Raatikainen P, Peuhkurinen KJ. Normothermic versus mild hypothermic retrograde blood cardioplegia: a prospective, randomized study. *Ann Thorac Surg* 1995;60:1087–93.
  17. Karadeniz U, Erdemli O, Yamak B, et al. On-pump beatingheart versus hypothermic arrested heart valve replacement surgery. *J Card Surg* 2008;23:107–13.
  18. Salerno TA, Panos AL, Tian G, Deslauriers R, Calcaterra D, Ricci M. Surgery for cardiac valves and aortic root without cardioplegic arrest (“beating heart”): experience with a new method of myocardial perfusion. *J Card Surg* 2007;22:459–64.